

BROILER HEALTH UPDATE

UNIVERSITY OF
MARYLAND
EXTENSION



Picture by Sean Cloughertv

GROWER LUNCH BREAK NOTES MAY 5, 2021

Jennifer Timmons, Assistant Professor at UMES, introduced our speaker and the new veterinarian, poultry diagnostician at the University of Delaware's Lasher Labs, **Dr. Nanette Olmeda-Geniec**, geniec@udel.edu.


Dr. Olmeda-Geniec gave us a little of her background, beginning with her small family farm in the mountains of Puerto Rico. Her new start at the University of Delaware (beginning at the 7:36 minute mark of the recording) she states the goals and service they would like to provide to the Delmarva Poultry Industry.

The talk can be seen at this link: <https://umd.hosted.panopto.com/Panopto/Pages/Viewer.aspx?id=af491e20-88c7-40fc-adca-ad1f01264206>


Dr. Olmeda-Geniec starts with an overview and breakdown of the different cases she has had since her start in January, 2021. She covers different viral and bacterial diagnosis and includes pictures and reasons for the causes, treatments, and what to look for early in your birds, vaccinations,

Respiratory Complex Diagnosis

- Can look like many respiratory diseases
 - Bronchitis, Newcastle, Ammonia, Aspergillus, etc.
 - Secondary bacterial infection
 - Important the age of the bird
 - Samples for diagnosis
- If LT is suspected, then treated as LT until Laboratory confirmation
- LT vaccination
 - Can be a necessary evil for LT outbreaks
 - Goal of vaccination: Eliminate the naïve population in the field
 - If properly done, can be very effective at controlling an LT outbreak



LT classic CLINICAL SIGNS



Some of the topics Dr. Nanette touched on, many with pictures:

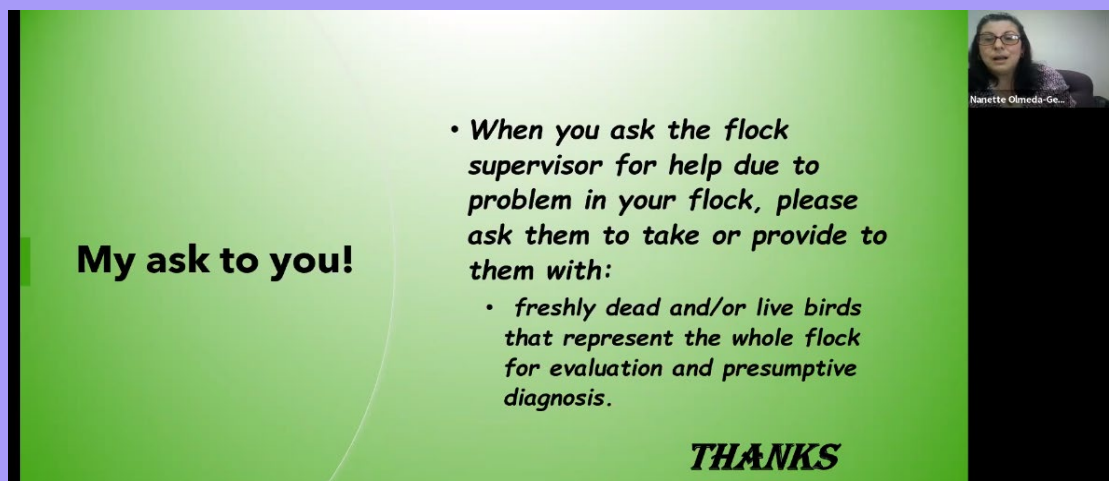
Bacterial or Viral Enteritis
Asphyxiation (Secondary Vaccine Reaction)
Trachea Gross Lesion
Syrinx Gross Lesions
Severe Airsacculitis
Foot Pad Infections

Respiratory Complex Diagnosis
LT Classic, Clinical Signs
Gastrointestinal Complex, Coccidiosis + Gangrenous Dermatitis
Necrotic Enteritis
Coccidiosis +NE
Respiratory Problems and Volvulus

(Topics continued)

Miscellaneous Gross Lesions (Tibial Dychondroplasia, Osteomyelitis, Pericarditis, Perihepatitis, Airsacculitis)
 Intussusception
 IBH (Inclusion Body Hepatitis)

Breast Muscle Trauma
 Mouth Lesions



My ask to you!

- *When you ask the flock supervisor for help due to problem in your flock, please ask them to take or provide to them with:*
 - *freshly dead and/or live birds that represent the whole flock for evaluation and presumptive diagnosis.*

THANKS

At the end of the presentation, Dr. Timmons asked Dr. Olmeda-Geniec the questions listed in the 'Chat' during the talk. If you click on the word 'Discussion' at the top left of the recorded page (under Pantopto), you will be able to see all the questions asked. **And the answers are given starting at the 43:00 minute mark.**

Also Jenny Rhodes asks if something is sent to her lab, does the grower get a report? Dr. Nanette says reports go to company and service techs, so they will be available to growers through the service techs.

Questions of viral and bacterial infections, windrowing decreasing viral loads, antibiotics, dark times on bird health, etc.

Thank you Dr. Olmeda-Geniec! Great presentation!

COMING EVENTS!

DCA's Maureen Duffy (duffy@dcachicken.com) - **Booster BBQ Event** June 18 at Delaware State Fairgrounds:
<https://www.dcachicken.com/booster-bbq/>

University of Delaware's Georgie Cartanza (cartanza@udel.edu) - **Mass Emergency Carcass Disposal Training**
 This program will offer 6 Continuing Education Credits. Let Georgie know if you would like more information

Look for next **Grower Lunch Break with Extension** information for the first Wednesday in each coming month!
 Register at: <https://umd.zoom.us/meeting/register/tJ0kfuyhqjsgNzp8wlhemiV6PeHRsJpxntO>



The University of Maryland is and Equal Opportunity Employer with Equal Access Programs